

ORTHOPEDIC TECHNOLOGIES & TECHNIQUES

an original study

Safety and Efficacy of Extracorporeal Shock Wave Therapy for Chronic Lateral Epicondylitis

John P. Furia, MD

ABSTRACT

Efficacy and safety of extracorporeal shock wave therapy (ESWT) were investigated in 36 patients with chronic lateral epicondylitis—9 patients receiving and 27 patients not receiving worker's compensation. All patients were treated with a single application of 3200 shock waves. Twelve weeks after treatment, the mean visual analog scale score for the entire group improved from 8.0 to 2.5 ($P < .05$), and the mean RAND 36-Item Health Survey (Physical Functioning) score improved from 65.6 to 88.0 ($P < .05$). Outcomes for 28 elbows (77.8%) were rated excellent or good on the Roles and Maudsley scale. There were no significant differences in outcome measures among the subgroups. There were no significant complications. ESWT is an effective treatment for chronic lateral epicondylitis. Worker's compensation status did not affect outcomes.

Lateral epicondylitis is a common enthesopathy of the elbow. Nirsch¹ and Kraushaar and Nirsch² showed that the primary lesion is an angiofibroblastic degeneration of the extensor origin. Cyriax³ noted that the origin of the extensor carpi radialis brevis is the usual site of injury, though the pathology may also originate in the extensor digitorum communis or extensor carpi radialis longus.⁴

The condition typically occurs in the fourth and fifth decades.^{5,6} Males and females are affected equally.⁷ An estimated 4 in 1000 individuals from the

general population are affected at some time.⁸ Manual workers and racquet sport athletes are at high risk.^{1,6,9-12} Indeed, lateral epicondylitis occurs in more than 50% of tennis players at one time or another in their careers.¹³

Lateral epicondylitis is a frequent cause of missed work.^{14,15} In a review of all worker's compensation (WC) claims accepted over 1 year by the US Department of Labor, investigators noted that enthesopathy of the elbow was the second most costly upper extremity diagnosis, accounting for 16% of total claims.¹¹ Silverstein and colleagues¹² noted that, unlike the claims rate for other upper extremity diagnoses, the rate for elbow epicondylitis was increasing. Results from a study in the Netherlands showed that 10% to 30% of all episodes of lateral epicondylitis resulted in absence from work (mean absence, 12 weeks).¹⁶

There is no consensus as to optimal form of treatment. Traditional nonoperative treatment consists of rest, activity modification, anti-inflammatory medications, various forms of physical therapy, forearm bracing, and steroid injections.^{1,16} Although rare, serious complications have been associated with steroid injections.^{17,18} In the majority of cases, nonoperative measures are effective.^{6,14}

Surgery is usually reserved for chronic cases. Surgical options include open or percutaneous release of the extensor tendons, localized excision of pathologic tissue, and arthroscopic débridement of the tendon origin.¹⁹⁻²¹ Success rates vary from series to series.^{2,4,19-21}

Extracorporeal shock wave therapy (ESWT) is a byproduct of lithotripter technology. ESWT has been used in Europe since the late 1980s and has been effective in treating various orthopedic conditions, including plantar fasciitis, shoulder calcific tendinitis, Achilles tendinitis, and nonunion of fractures of long bones.²²⁻²⁸

Dr. Furia is Team Physician for Bucknell University and is in private practice, SUN Orthopedics and Sports Medicine, Lewisburg, Pennsylvania.

Address correspondence to John P. Furia, MD, SUN Orthopedics and Sports Medicine, 900 Buffalo Rd, Lewisburg, PA 17837 (tel. 570-524-4446; fax 570-522-1110; email, jfuria@sunortho.com)

In 1996, Rompe and colleagues²⁹ described using ESWT to treat chronic elbow tendinitis. Pain was reduced and grip strength improved significantly more in treated than in control patients. Subsequent trials³⁰⁻³⁶ have substantiated these results.

In July 2002, the US Food and Drug Administration (FDA) approved a low-energy shock wave device for treating chronic lateral epicondylitis,³⁶ and, in 2003, the FDA approved a high-energy device for treating chronic lateral epicondylitis.³⁵

Results from several recent studies, however, have cast doubt on the efficacy of ESWT in treating chronic tendinopathies.³⁷⁻³⁹ The purpose of the present study was to examine the efficacy and safety of ESWT in treating chronic lateral epicondylitis and to determine whether there are any differences in outcome between patients with and without an open WC claim. The hypothesis was that ESWT would be an effective treatment for each cohort of patients.

Methods

From June 2002 to June 2003, all patients with chronic lateral epicondylitis treated with ESWT by a member of the American Kidney Stone Management-Orthopedics network were considered for inclusion in the study.

For this study, lateral epicondylitis was defined as symptoms of moderate to severe lateral elbow pain that worsened with repetitive forearm motion. All patients were evaluated through history taking and physical examination, and all exhibited clinical signs and symptoms of lateral epicondylitis. All patients exhibited tenderness over the common extensor origin and had pain with resisted wrist extension.

Patients included in the study had an established diagnosis of chronic lateral epicondylitis for at least 6 months before treatment and had undergone at least 3 forms of traditional nonoperative treatment without success. Traditional nonoperative treatment consisted of rest, anti-inflammatory medication, ice, massage, forearm bracing, stretching, physical therapy, and steroid injections.

Exclusion criteria were rheumatoid arthritis, generalized polyarthritis, Reiter syndrome, local infection, pregnancy, bleeding disorders, tumors, age younger than 18, severe endocrine disease, advanced peripheral vascular disease, and previous lateral epicondylitis surgery.

All patients signed an informed consent form. Procedure details and potential risks were discussed fully before treatment.

All treatments were performed on an outpatient basis with either local anesthesia or a regional block. Physician and patient chose the type of anesthesia. When a local anesthesia was used, the skin and subcu-

aneous tissues overlying the common extensor origin were numbed with approximately 10 to 15 mL of 1% lidocaine solution. Regional anesthesia was administered by a member of the anesthesia department. Patients treated with "straight local" anesthesia did not receive intravenous sedation. Patients treated with a regional block received intravenous sedation on an as-needed basis as determined by the anesthesia provider.

A blood pressure cuff was applied to the nonaffected arm. A coupling gel was applied to the lateral aspect of the elbow. The patient's vital signs and local discomfort were monitored throughout the procedure.

A Dornier Epos lithotripter (Dornier MedTech Inc, Kennesaw, Ga) was used to administer ESWT. This lithotripter has an electromagnetic coil that generates shock waves.⁴⁰ Shock waves are guided using ultrasonographic localization of the region of interest, are focused on the area of maximal tenderness and on the surrounding area, and are delivered in a lateral-to-medial direction.

ESWT was administered once to each patient using a standard protocol. The patient was given a total of 3200 shocks for a total energy flux density of 1085 mJ/mm². Fifty shocks were given at each power level from 1 through 6, for a total of 300 shocks. The final 2900 shocks were given at power level 7. Frequency of shock wave administration was increased from 60 shocks/min at power level 1 to 240 shocks/min at power level 7.

On completion of the procedure, the treated elbow was assessed for hematoma, bruising, and swelling. The patient was discharged from the same-day holding area with instructions to ice and rest the elbow. After treatment, some physicians applied splinting for a brief period. No other interventions were used.

The patient was allowed early range of motion. If a splint had been used, it was removed within several days after treatment. Activity was advanced as symptoms dissipated. The patient returned to pretreatment work status within a week after treatment. How much time to take off before returning to sports was decided on a case-by-case basis.

Follow-up examinations were scheduled for 4 weeks and 12 weeks after treatment. The patient was also contacted by telephone for a survey. Outcome measures included visual analog scale (VAS) scores, RAND 36-Item Health Survey (Physical Functioning) scores, and Roles and Maudsley scale scores.

VAS scores (10 = severe pain, 0 = no pain) were collected before treatment and 4 and 12 weeks after treatment. Paired Student *t* test with statistical significance set at $P < .05$ was used to compare the scores collected at these 3 times.

The RAND 36-Item Health Survey is a validated instrument for assessing 8 health concepts.⁴¹ RAND

Physical Functioning scores (100 = perfect physical functioning, 0 = severe loss of physical functioning) were collected before treatment and 4 and 12 weeks after treatment. Paired Student *t* test with statistical significance set at $P < .05$ was used to compare the scores collected at these 3 times.

The Roles and Maudsley scale²³ is a subjective 4-point rating scale used by many investigators reporting ESWT results.²⁴⁻²⁶ On this scale, results are rated excellent (patient has no symptoms), good (patient's condition is significantly improved, patient is satisfied), fair (patient's condition is somewhat improved, patient is partially satisfied), or poor (patient's condition is the same or worse, patient is dissatisfied). Each patient rated the pretreatment condition of his or her elbow as excellent, good, fair, or poor. Roles and Maudsley scores were collected 4 and 12 weeks after treatment. Paired Student *t* test with statistical significance set at $P < .05$ was used to compare the outcome variables.

Results

Of the 50 patients (56 elbows) treated, 14 were excluded from analysis: 6 who had both elbows treated during the study period, 4 who were treated with both ESWT and plasmapheresis by a single physician (plasmapheresis could be a confounding variable), and 4 whose follow-up data were insufficient. Thus, after 3 months, 36 patients (36 elbows) were available for analysis. All 36 patients (15 women, 21 men) were seen in follow-up by their treating physician and were contacted by telephone 1 and 3 months after treatment. Mean age was 43 years (range, 26-61 years). Mean condition duration was 19 months (range, 8-48 months).

Visual Analog Scale Scores

Mean VAS score was 8.0 (SD, 1.5) before treatment versus 4.0 (SD, 2.0) 4 weeks after treatment. The decrease is statistically significant ($P < .05$) (Figure 1). Twelve weeks after treatment, mean VAS score was 2.5 (SD, 2.3). The decrease from before treatment to 12 weeks after treatment is also statistically significant ($P < .05$) (Figure 2).

RAND Physical Functioning Scores

Mean RAND Physical Functioning score was 65.6 (SD, 18.3) before treatment versus 80.8 (SD, 11.6) 4 weeks after treatment. The increase is statistically significant ($P < .05$). Twelve weeks after treatment, mean RAND Physical Functioning score was 88.0 (SD, 12.3). The increase from before treatment to 12 weeks after treatment is also statistically significant ($P < .05$).

Roles and Maudsley Scale Scores

Table I summarizes Roles and Maudsley scale scores collected before treatment and 4 and 12

weeks after treatment for all elbows. Before treatment, all patients rated the condition of their affected elbow as poor. Four weeks after treatment, 6 elbows (16.7%) were rated excellent, and 19 (52.8%) were rated good. Twelve weeks after treatment, 7 elbows (19.4%) were rated excellent, and 21 (58.3%) were rated good. No patient reported a worsening of symptoms from his or her pretreatment status.

Patients Receiving Worker's Compensation

Nine patients were receiving WC for their elbow injury. Mean VAS and RAND Physical Functioning scores before treatment and 4 and 12 weeks after

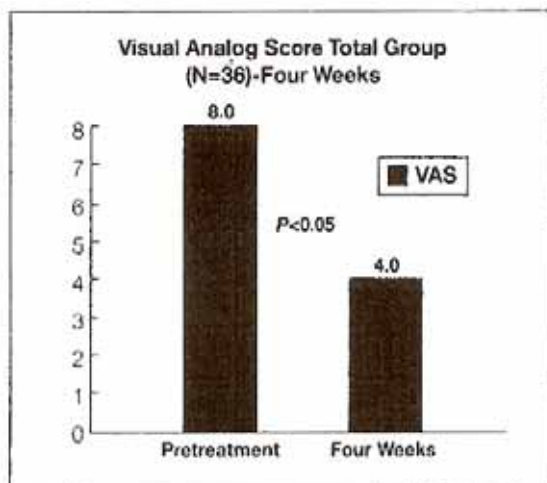


Figure 1. Mean visual analog scale score for all 36 patients 4 weeks after extracorporeal shock wave therapy. Difference in mean scores before and 4 weeks after treatment is statistically significant ($P < .05$).

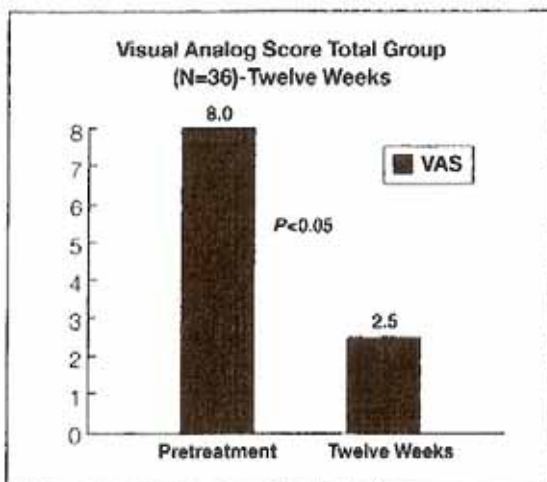


Figure 2. Mean visual analog scale score for all 36 patients 12 weeks after extracorporeal shock wave therapy. Difference in mean scores before and 12 weeks after treatment is statistically significant ($P < .05$).

TABLE I. ROLES AND MAUDSLEY SCALE SCORES 4 AND 12 WEEKS AFTER TREATMENT*

Score n (%)	4 Wk	12 Wk
Excellent	6 (16.7%)	7 (19.4%)
Good	19 (52.8%)	21 (58.3%)
Fair	7 (19.4%)	4 (11.1%)
Poor	4 (11.1%)	4 (11.1%)

*N = 26 patients.

TABLE II. VISUAL ANALOG SCALE SCORES AND RAND PHYSICAL FUNCTIONING SCORES BEFORE TREATMENT*

Patients	Visual Analog Score	RAND Physical Functioning Score
WC	7.3 ± 1.8	67.8 ± 23.3
Non-WC	8.3 ± 1.3	64.9 ± 17.2
All	8.0 ± 1.5	65.6 ± 18.3

*WC indicates worker's compensation. There is no statistical difference in mean visual analog scale scores or mean RAND Physical Functioning scores among the groups of patients before treatment ($P > .05$).

treatment are summarized in Tables II to IV. There is no statistical difference in mean VAS score or mean RAND Physical Functioning score between WC patients and the entire group ($P > .05$ for each outcome measure) (Tables II–IV). Four weeks after treatment, no elbows were rated excellent, 4 were rated good, 2 were rated fair, and 2 were rated poor. Twelve weeks after treatment, 1 elbow was rated excellent, 6 were rated good, 1 was rated fair, and 1 was rated poor.

Patients Not Receiving Worker's Compensation

Twenty-seven patients were not receiving WC. Mean VAS and RAND Physical Functioning scores before treatment and 4 and 12 weeks after treatment are summarized in Tables II to IV. There is no statistical difference in mean VAS score or mean RAND Physical Functioning score between non-WC patients and the entire group ($P > .05$ for each outcome measure) (Tables II–IV). Four weeks after treatment, 5 elbows were rated excellent, 15 were rated good, 5 were rated fair, and 2 were rated poor. Twelve weeks after treatment, 6 elbows were rated excellent, 15 were rated good, 3 were rated fair, and 3 were rated poor.

Complications

There were only 4 minor complications. For 2 patients, pain occurred during treatment but resolved

TABLE III. VISUAL ANALOG SCALE SCORES AND RAND PHYSICAL FUNCTIONING SCORES 4 WEEKS AFTER TREATMENT*

Patients	Visual Analog Score	RAND Physical Activity Score
WC	4.2 ± 2.9	75.9 ± 14.7
Non-WC	4.0 ± 1.9	84.7 ± 10.4
All	4.0 ± 2.0	80.8 ± 12.3

*WC indicates worker's compensation. There is no statistical difference in mean visual analog scale scores or mean RAND Physical Functioning scores among the groups of patients 4 weeks after treatment ($P > .05$).**TABLE IV. VISUAL ANALOG SCALE SCORES AND RAND PHYSICAL FUNCTIONING SCORES 12 WEEKS AFTER TREATMENT***

Patients	Visual Analog Score	RAND Physical Functioning Score
WC	2.3 ± 1.3	85.2 ± 17
Non-WC	2.5 ± 2.2	86.1 ± 20
All	2.5 ± 2.3	88 ± 12.3

*WC indicates worker's compensation. There is no statistical difference in mean visual analog scale scores or mean RAND Physical Functioning scores among the groups of patients 12 weeks after treatment ($P > .05$).

after treatment. Two patients had transitory skin-redness that resolved without intervention.

Discussion

The literature is replete with reports on the efficacy of ESWT in treating chronic lateral epicondylitis.^{16–18} After their initial 1996 report, Rompe and colleagues¹¹ in 2001 reported on another 30 patients with chronic unilateral lateral epicondylitis who also had clinical signs of cervical dysfunction. The investigators compared the effects of ESWT with the effects of a combination of ESWT and manual therapy on the cervical spine. All patients—those who had ESWT and those who had combination therapy—improved significantly since their pretreatment evaluation. The investigators concluded that ESWT is effective in treating chronic lateral epicondylitis and that cervical manual therapy is of questionable value.

Maier and colleagues¹⁴ reported on 42 patients who underwent ESWT for chronic lateral epicondylitis. Between pretreatment and 19-month follow-up, VAS scores improved significantly for 52% of female patients and 84% of male patients.

In a prospective study of 53 patients (56 elbows) with chronic lateral epicondylitis, Ko and colleagues¹² reported 36.7% excellent or good results 6 weeks after ESWT, 57.9% excellent or good results 12 weeks after treatment, and 73.1% excellent or good results 24

weeks after treatment. There were no complications.

Wang and Chen¹⁷ examined the effects of ESWT on 43 patients (44 elbows) with chronic lateral epicondylitis and reported that 90.9% of treated patients either had no complaints (61.4%) or had improved significantly since before treatment (29.5%). The 6 control patients (treated with traditional nonoperative therapies) did not improve significantly from their pre-treatment condition.

Day¹⁸ reported on 41 patients with work-related lateral epicondylitis lasting more than 6 months. After traditional nonoperative treatment failed for these patients, they were treated with either ESWT or surgery. Seventy-six percent of ESWT patients—versus only 30% of surgery patients—returned to work.

In the present study, the effects of ESWT were evaluated in a consecutive series of patients with chronic lateral epicondylitis that failed to respond to nonoperative management. The outcome for the entire study population was evaluated. The effect of WC status was analyzed.

Mean VAS and RAND Physical Functioning scores were improved 4 weeks and 12 weeks after treatment. The percentage of excellent or good results (Roles and Maudsley scale scores) 12 weeks after treatment was 77.8%. There were no significant complications, and no patient required additional ESWT.

In addition, there were no significant differences between WC patients and non-WC patients with respect to outcome measures. These findings are important, as lateral epicondylitis is a common work-related injury. In some surgical series, WC status has been identified as an outcome-influencing factor.¹⁹⁻²¹ Data from the present study suggest that WC status does not affect outcome with ESWT. Conceivably, maximum medical improvement can occur as soon as 3 months after initial ESWT. Indeed, in the present study, a positive effect was evident 3 months after ESWT. Further prospective work is needed to verify this result.

The FDA has approved several lithotripsy devices for treating various musculoskeletal conditions. Two devices, including the one used in this study, use electromagnetic energy to generate shock waves; another device uses electrohydraulic energy. Comparison studies have not been conducted on devices used for musculoskeletal lithotripsy.

ESWT is an emerging technology, and protocols vary from trial to trial. Different modes of delivering shock waves—single treatment versus multiple treatments, low energy (0.05–0.10 mJ/mm²) versus high energy, electromagnetic versus electrohydraulic generation—can all influence therapy outcomes. Patients treated with low-energy devices may require less anesthesia than patients treated with high-energy

devices. For this reason, the results reported in a study are valid only for the parameters applied in that study.

Some investigators have questioned the efficacy of ESWT. Haake and colleagues²² studied the effects of ESWT and placebo on chronic lateral epicondylitis. There were 135 patients in the ESWT group and 137 patients in the placebo group. After withdrawing 11 patients from the ESWT group and 15 patients from the placebo group because of missing data, the investigators found no statistical difference between the ESWT and placebo groups in number of patients with a good or excellent pain score (Roles and Maudsley scale).

Crowther and colleagues²³ compared the analgesic effects of injected steroid and ESWT in treating lateral epicondylitis. Patients received either a single injection of triamcinolone 20 mg with lidocaine or 2000 shock waves in 3 sessions at weekly intervals. After 3 months, treatment was deemed successful in 84% of patients treated with steroid and in 60% of patients treated with ESWT.

Speed and colleagues²⁴ analyzed the results of ESWT on 40 patients with chronic lateral epicondylitis and 35 sham-treated patients with the same diagnosis. Three months after treatment, there was 50% pain improvement in 35% of treated patients and 34% of sham-treated patients. "Chronic" lateral epicondylitis was defined as lateral elbow pain lasting for at least 3 months. Mean duration of this symptom was 15.9 months in treated patients versus 12 months in sham-treated patients. Median duration of the symptom was not reported.

These negative studies and the present study differ in important ways. First, Haake and colleagues²² administered ESWT in 3 separate 2000-impulse treatments separated by 7 days (SD, 1 day), and Crowther and colleagues²³ administered ESWT in 3 weekly sessions, whereas ESWT was given in a single, larger dose in this study.

Second, the treatment parameters used by Speed and colleagues²⁴ (3 monthly "moderate-energy" ESWT doses of 1500 pulses at 0.12 mJ/mm²) are very different from those used in the present study (1 "high-energy" dose).

Third, Crowther and colleagues²³ enrolled patients who were symptomatic for at least 4 months, and Speed and colleagues²⁴ enrolled patients who were symptomatic for 3 months, whereas this study enrolled patients who were symptomatic for a minimum of 6 months. In my experience, patients with less chronic symptoms (<6 months) are likely to improve with or without ESWT.

ESWT results are valid only for the therapeutic parameters applied. Patient selection and treatment technique (adequate number of shocks, adequate total

dose) are critical. Differences in results between different trials may be related to heterogeneity of treatment parameters (eg, total dose, interval between doses, number of sessions), study populations (rural vs university), and perhaps machine design. Further work is needed to clarify these issues.

Being retrospective, this study has some inherent weaknesses. Follow-up was only 3 months (though other, larger studies have used a similar follow-up period^{30,37-39}). In addition, different physicians at different centers performed the procedures, so the degree of success reported here could in part be provider-dependent (probably unlikely, as the shock wave generator and application protocol were identical in all cases). Finally, this study did not use a control group.

Nevertheless, this series contributes valuable information. Data from this study show that ESWT is safe and effective for treating chronic lateral epicondylitis resistant to traditional therapy.

Summary

ESWT is an excellent treatment for chronic lateral epicondylitis resistant to traditional treatment. The ESWT procedure used in the present study was consistently associated with pain relief and functional improvement. There were no apparent differences in outcome between patients with and without WC claims. As previously reported,²⁹⁻³¹ ESWT appeared safe and effective. Unlike recovery from surgery, recovery from ESWT generally occurs without significant morbidity. Further prospective work is under way to better define this new modality.

Author's Disclosure Statement

Dr. Furia wishes to note that he is a medical director with American Kidney Stone Management/Orthopedics, Inc.

References

- Nirschl RP. Elbow tendinosis/tennis elbow. *Clin Sports Med*. 1992;11:851-870.
- Kraushaar BS, Nirschl RP. Tendinosis of the elbow (tennis elbow). *J Bone Joint Surg Am*. 1999;81:259-278.
- Cyriax JH. The pathology and treatment of tennis elbow. *J Bone Joint Surg Am*. 1936;18:921-940.
- Nirschl RP. Tennis elbow tendinosis: pathoanatomy, nonsurgical and surgical management. In: Gordon SL, Blair SJ, Fine LJ, eds. *Repetitive Motion Disorders of the Upper Extremity*. Rosemont, Ill: American Academy of Orthopaedic Surgeons; 1995:467-479.
- Nirschl RP, Petrone FA. Tennis elbow: the surgical treatment of lateral epicondylitis. *J Bone Joint Surg Am*. 1979;61:832-839.
- Job FW, Cicotti MG. Lateral and medial epicondylitis of the elbow. *J Am Acad Orthop Surg*. 1994;2:1-8.
- Gruchow HW, Pelletier D. An epidemiological study of tennis elbow: incidence, recurrence, and effectiveness of prevention strategies. *Am J Sports Med*. 1979;7:234-238.
- Hamilton PG. The prevalence of humeral epicondylitis: a survey in general practice. *J R Coll Gen Pract*. 1986;36:464-465.
- Lewis M, Hay EM, Patterson SM, Croft P. Effects of manual labor on recovery from lateral epicondylitis. *Scand J Work Environ Health*. 2002;28:109-116.
- Assendelft WJ, Hay EM, Bouter AR. Corticosteroid injections for lateral epicondylitis: a systematic overview. *Br J Gen Pract*. 1996;46:209-216.
- Feuerstein M, Miller VL, Burrell LM, Berger R. Occupational upper extremity disorders in the federal workforce—prevalence, health care expenditures, and patterns of work disability. *J Occup Environ Med*. 1998;40:546-555.
- Silverstein B, Vaccaria-Juntura E, Kalat J. Use of a prevention index to identify industries at high risk for work-related musculoskeletal disorders of the neck, back, and upper extremity in Washington state, 1990-1998. *Am J Ind Med*. 2002;41:149-169.
- Morris M, Jobe FW, Perry J. Electromyographic analysis of elbow function in tennis players. *Am J Sports Med*. 1989;17:241-247.
- Labelle H, Guibert R, Joncas J, Newman N, Follaha M, Rivard CH. Lack of scientific evidence for the treatment of lateral epicondylitis of the elbow. *J Bone Joint Surg Br*. 1992;74:646-651.
- Dimberg L. The prevalence and causation of tennis elbow (lateral humeral epicondylitis) in a population of workers in an engineering industry. *Ergonomics*. 1987;30:573-579.
- Hart LE. Corticosteroid injections, physiotherapy, or a wait-and-see policy for lateral epicondylitis? *Clin J Sport Med*. 2002;12:403-404.
- Jawed S, Allard A. Osteomyelitis of the humerus following steroid injections for tennis elbow. *Rheumatology*. 2000;39:923-924.
- Almekinders LC. Tendinitis and other chronic tendinopathies. *J Am Acad Orthop Surg*. 1998;6:157-164.
- Baker CL, Murphy KP, Gottlob CA, Curd DT. Arthroscopic classification and treatment of lateral epicondylitis: two-year clinical results. *J Shoulder Elbow Surg*. 2000;9:475-482.
- Organ SW, Nirschl RP, Kraushaar BS, Guidi EJ. Salvage surgery for lateral tennis elbow. *Am J Sports Med*. 1997;25:746-750.
- Verhaar J, Walenkamp G, Kester A, van Mameren H, van der Linden T. Lateral extensor release for tennis elbow: a prospective long-term follow-up study. *J Bone Joint Surg Am*. 1993;75:1034-1043.
- Rompe JD, Schoellner C, Nafe B. Evaluation of low energy extracorporeal shock wave treatment for treatment of chronic plantar fasciitis. *J Bone Joint Surg Am*. 2002;84:335-341.
- Ogden JA, Alvarez RQ, Levitt R, et al. Shock wave therapy for chronic plantar fasciitis. *Clin Orthop*. 2001;387:47-59.
- Wang CJ, Yang KD, Wang FS. Shock wave therapy for calcific tendonitis of the shoulder. *Am J Sports Med*. 2003;31:425-430.
- Vakhanou VD, Michailov P. High energy shock wave is the treatment of delayed and nonunion of fractures. *Int Orthop*. 1991;15:181-184.
- Haupt G. Use of extracorporeal shockwaves in the treatment of pseudoarthrosis, tendinopathy, and other orthopedic diseases. *J Urol*. 1997;158:4-11.
- Backman C, Boquist L, Friden J, Lorentzon R, Toolanen G. Chronic Achilles paratenitis with tendinosis: an experimental model in the rabbit. *J Orthop Res*. 1990;8:541-547.
- Rompe JD, Kirkpatrick CJ, Kullmer K, Schwitalfe M, Krschek O. Dose-related effects of shock waves on rabbit tendo Achilles. *J Bone Joint Surg Br*. 1998;80:546-552.
- Rompe JD, Hopf C, Kullmer K, Heine J, Burger R. Analgesic effects of extracorporeal shock wave therapy on chronic tennis elbow. *J Bone Joint Surg Br*. 1996;78:233-237.
- Rompe JD, Hopf C, Kullmer K, Heine J, Burger R, Nafe B. Low-energy extracorporeal shock wave therapy for persistent tennis elbow. *Int Orthop*. 1996;20:23-27.
- Rompe JD, Riedel C, Betz U, Fink C. Chronic lateral epicondylitis of the elbow: a prospective study of low-energy shockwave therapy and low-energy shockwave therapy plus manual therapy of the cervical spine. *Arch Phys Med Rehabil*. 2001;82:578-582.
- Ko JY, Chen HS, Chen LM. Treatment of lateral epicondylitis of the elbow with shock waves. *Clin Orthop*. 2001;387:60-67.
- Wang CJ, Chen HS. Shock wave therapy for patients with lateral epicondylitis of the elbow. *Am J Sports Med*. 2002;30:422-429.
- Maier M, Steinborn M, Schmitz C, et al. Extracorporeal shock-wave therapy for chronic lateral epicondylitis—prediction of outcome by imaging. *Arch Orthop Trauma Surg*. 2001;121:379-384.
- Dunham RC, Lingeran RJ. Treatment of chronic lateral epicondylitis with shock wave therapy (OssaTron): a multicenter, blinded, randomized, placebo-controlled study of safety and efficacy. Paper presented at: Annual Meeting of the Sixth Congress of the International Society for Musculoskeletal Shockwave Therapy; February 10-13, 2003; Orlando, Fla.

36. Pettrone F, Lefson CS, Romness DW, McCall BR, Covall DJ, Boatright JR. Evaluation of extracorporeal shock wave therapy for chronic lateral epicondylitis. Paper presented at: Annual Meeting of the American Academy of Orthopaedic Surgeons; February 13-17, 2002; Dallas, Tex.
37. Huske M, Konig JR, Decker T, Riedel C, Buch M, Müller HH. Extracorporeal shock wave therapy for the treatment of lateral epicondylitis: a randomized multicenter trial. *J Bone Joint Surg Am.* 2002;84:1982-1991.
38. Speed CA, Nicholas D, Richards C, et al. Extracorporeal shock wave therapy for lateral epicondylitis—a double blind randomized controlled trial. *J Orthop Res.* 2002;20:895-898.
39. Crowther MA, Bannister GC, Huma H, Rooker GD. A prospective, randomized study to compare extracorporeal shock-wave therapy and injection of steroid for the treatment of tennis elbow. *J Bone Joint Surg Br.* 2002;84:678-679.
40. Dornier MedTech Inc. *Dornier Equis Ultra: Summary of Safety and Effectiveness Data.* Kennesaw, Ga: Dornier MedTech Inc; 2002.
41. Hays RD, Sherbourne CD, Mazel RM. The RAND 36-Item Health Survey 1.0. *Health Econ.* 1993;2:217-227.
42. Roles NC, Maudsley RH. Radial tunnel syndrome: resistant tennis elbow as a nerve entrapment. *J Bone Joint Surg Br.* 1972;54:499-508.
43. Rompe JD, Decking J, Schoelner C. Shock wave application for chronic plantar fasciitis in running athletes. *Am J Sports Med.* 2003;31:268-275.
44. Maier M, Steinborn M, Schmitz C. Extracorporeal shock wave application for chronic plantar fasciitis associated with heel spurs: prediction of outcome by magnetic resonance imaging. *J Rheumatol.* 2000;27:2455-2462.
45. Day B. Clinical focusing and low energy ESWT in the treatment of work-induced chronic lateral epicondylitis. Paper presented at: Annual Meeting of the Sixth Congress of the International Society for Musculoskeletal Shock-wave Therapy; February 10-13, 2003; Orlando, Fla.
46. Nicholson GP. Arthroscopic acromioplasty: a comparison between workers' compensation and non-workers compensation populations. *J Bone Joint Surg Am.* 2003;85:682-689.
47. Hawkins RJ, Plancher KD, Sadelmi SR, Brezenoff LS, Moor JT. Arthroscopic subacromial decompression. *J Shoulder Elbow Surg.* 2001;10:225-230.
48. Broye RP, Grana WA, Yates CK. Arthroscopic subacromial decompression: two to seven year follow-up. *Arthroscopy.* 1995;11:301-306.
49. Stephens SR, Warren RF, Payne LZ, Wickiewicz TL, Alchek DW. Arthroscopic acromioplasty: a 6 to 10 year follow up. *Arthroscopy.* 1998;14:382-388.

Commentary

Approximately 17 million new patients are thought to be afflicted with tendinosis or tendinitis in the United States per year. There have been no new technological advancements until recently for treating this entity. Those two advancements are extracorporeal shock wave therapy (ESWT) as summarized very nicely by Dr. Furia's article, and the use of plasma radiofrequency (RF)-based technology (TOPAZ™, ArthroCare Corp., Sunnyvale, California). The use of ESWT and RF-based microtenotomy are reserved for the failure of conservative measures. One needs to keep in mind that conservative care is not always conservative, and complications do exist, such as the alarming and high incidence of GI bleeds with nonsteroidal anti-inflammatories. Traditional surgery has generally consisted of some form of débridement with reasonably good results, but with prolonged rehabilitation and very little scientific support for the mechanism of action of these procedures.

Tendinosis is a pathological condition consisting of disorganized collagen, avascular tendon fascicles, hypertrophy of the fibroblasts, and reduced nutri-

tional flow to the tenocyte. This leads to hypovascular zones and subsequent pathological conditions. Our lab has extracted RNA in cases with torn rotator cuffs and compared them to normal rotator cuffs and have found significant reductions of vascular endothelial growth factor (VEGF) and alpha-V integrin. This would lead one to believe that a reduction in these growth factors plays an important role in tendinosis.

There are multiple other articles in the European as well as American literature on the efficacy of ESWT. There are mixed reviews and certainly some controversy as to its effectiveness. The majority of the articles are favorable, however, and those that are unfavorable on occasion had flaws in the scientific methodology used. Our experience with the in-office low-energy shock wave therapy (Sonocur®; Fayetteville, North Carolina) has been reasonably good. We feel that two-thirds of the patients have improved, and their level of improvement approaches 70%. We have found it most efficacious in patients who are athletes whose sport is in season, and in patients who cannot take time off to undergo a surgical procedure for other reasons. We have chosen low-energy rather than the high-energy shock wave therapy because of convenience for the patient as well as cost effectiveness.

The use of plasma RF-based microtenotomy has been popularized over the past 2 1/2 years. It appears to be a very safe and efficacious minimally surgical procedure when conservative care fails. There are rather impressive findings in the literature to support the acceleration of a variety of growth factors with the use of a very-low-dose radiofrequency device. Studies have been done in the myocardium as well as in the vertebral disc and also in healing wounds to support acceleration of a variety of these growth factors. Our clinical experience with this over the last 2 1/2 years has yielded excellent results in more than 90% of the patients. The complication rate is almost nonexistent, and the patients' rehabilitation process is accelerated and rapid.

The socioeconomic issues are paramount in both of these technologies. Insurance remuneration for ESWT has been slow in its evolution, although it is a very cost-effective procedure. The insurance remuneration for microtenotomy has not been a problem because it is a variation on a traditional approach to this condition. Both of these approaches appear to be cost-effective and should be appealing to the insurance industry, not only because of overall cost reduction, but also reductions in time off work from injuries, surgery, and prolonged rehabilitation.

James P. Tasto, MD
San Diego, California